

Effect of Human Bone Marrow Mesenchymal Stem Cells on Burn Healing in Granulation Tissue Formation in Diabetic Rats

Gusti Revilla¹, Deddy Saputra², Dini Nurhasanah³

Abstrak

Luka bakar dengan kondisi diabetes melitus dapat mengganggu dalam proses penyembuhan luka. Mesenchymal stem cell telah diteliti dapat mempercepat penyembuhan luka bakar salah satunya yang berasal dari sumsum tulang. **Objektif:** Menentukan pengaruh human Bone Marrow Mesenchymal Stem Cells (hBM-MSCs) terhadap penyembuhan luka bakar pada pembentukan jaringan granulasi tikus Diabetes Mellitus. **Metode:** Penelitian ini adalah studi eksperimental dengan rancangan *post-test only control group design*, menggunakan 30 ekor tikus dibagi menjadi dua kelompok, kelompok kontrol dengan Phosphate Buffer Saline (PBS) dan kelompok perlakuan dengan hBM-MSCs. Tikus diinduksi aloksan agar terjadi hiperglikemia. Luka bakar dibuat menggunakan plate yang di panaskan. Pengambilan jaringan dilakukan setelah terminasi hewan coba pada hari ke-3, ke-7 dan ke-14 kemudian dilakukan pembuatan preparat histologis untuk menilai pembentukan jaringan granulasi. Data dianalisis menggunakan uji *Two Way ANOVA*. **Hasil:** Terjadinya peningkatan jumlah makrofag, fibroblas dan pembuluh darah baru setelah diberikan hBM-MSCs. Pada neutrofil hari ke-14 dan limfosit hari ke-3 tidak terjadi peningkatan. Analisis statistik menunjukkan terjadi peningkatan yang bermakna dari jumlah limfosit, makrofag, fibroblast dan pembuluh darah baru. **Simpulan:** human bone marrow mesenchymal stem cells dapat meningkatkan pembentukan jaringan granulasi dengan meningkatkan jumlah makrofag, fibroblast dan pembuluh darah baru pada tikus diabetes.

Kata kunci: human bone marrow mesenchymal stem cells, jaringan granulasi, luka bakar, tikus diabetes

Abstract

*Burns with diabetes mellitus can interfere with the wound-healing process. Mesenchymal stem cells have been studied to accelerate the healing of burns, one of which originates from the bone marrow. **Objective:** To determined the effect of human bone marrow mesenchymal stem cells (hBM-MSCs) on burn wound healing in granulation tissue formation in Diabetes Mellitus rats. **Methods:** This study was an experimental study with a post-test-only control group design, using 30 rats divided into two groups, the control group Phosphate Buffer Saline (PBS) and the treatment group (hBM-MSCs). Mice were induced by alloxan to cause hyperglycemia. Burns are made using a heated plate. Tissue collection was carried out after the termination of the experimental animals on the 3rd, 7th and 14th days and then histological preparations were made to assess the formation of granulation tissue. Data were analyzed using the two-way ANOVA test. **Results:** There was an increase in the number of macrophages, fibroblasts and new blood vessels after being given hBM-MSCs. On day 14 neutrophils and lymphocytes on day 3, there was no increase. Statistical analysis showed a significant increase in lymphocytes, macrophages, fibroblasts and new blood vessels. **Conclusion:** Human bone marrow mesenchymal stem cells can increase the formation of granulation tissue by increasing the number of macrophages, fibroblasts and new blood vessels in diabetic rats.*

Keywords: burn wound, diabetic rat, human bone marrow mesenchymal stem cells, granulation tissue

Author affiliation: ¹Department of Anatomy, Faculty of Medicine, Universitas Andalas, Indonesia. ²Department of Surgery, Faculty of Medicine, Universitas Andalas, Indonesia. ³Faculty of Medicine, Universitas Andalas, Indonesia.

Correspondence: Gusti Revilla, Email: gustirevillaelok@yahoo.com

INTRODUCTION

Burns have a high prevalence and incidence and are a significant cause of morbidity and mortality in the world.¹ In severe burns, the cells and blood vessels are often injured and the blood supply to the wound is disturbed.²

Skin damage due to burns depends on the depth and area of the burn, so proper and appropriate handling is necessary to speed up the wound-healing process.³ Skin wounds, including burns, will generally experience a healing process consisting of several overlapping phases: inflammation, proliferation and remodeling.⁴ During the proliferative phase, the wound will be filled with inflammatory cells, fibroblasts, collagen and the formation of new blood vessels so that a reddish-colored tissue with an irregular and rough appearance is seen. This condition is called granulation tissue.⁵ The formation of granulation tissue in This proliferative phase is very important in wound healing because it can speed up the healing process of burns.⁶

Wound healing in diabetics tends to take longer due to the occurrence of hyperglycemia, which is an increase in blood sugar levels that can bind oxygen so that the hypoxic state lasts longer. The presence of prolonged hypoxia can reduce, among other things, the amount of Vascular Endothelial Growth Factor (VEGF) levels which play a role in the process of angiogenesis in wound healing.^{7,8} Diabetic conditions also cause dysfunction of the inflammatory response and decrease in the formation of granulation tissue and an increase in apoptosis of fibroblasts.⁹

Treatment of burns has now been carried out with cell therapy, namely using stem cells or stem cells.¹⁰ Stem cells are cells capable of self-replication and can form specialized cells.¹¹ Several researchers have previously proven that therapy with human mesenchymal stem cells can be used for the treatment of various diseases because of its regenerative, immunomodulator and differentiation capabilities, which can be applied to specific skin treatments such as those that have been widely studied for the treatment of cuts and burns.¹²

Stem cells come from various parts, including bone marrow or Bone Marrow Mesenchymal Stem Cells (BM-MSCs). BM-MSCs are stem cells that are

multipotent progenitors and can also differentiate to form osteoblasts, chondrocytes, myocytes, adipocytes, epithelial cells, neuron cells, fibroblasts, myofibroblasts, keratinocytes and endothelial cells.¹³ Human Bone Marrow –Mesenchymal Stem Cells are stem cells which is promising for cytotrapy because it is easy to isolate and has been shown to differentiate into various cell lineages.¹⁴

The advantage of other hBM-MSCs is that they have a high level of differentiation and proliferation in the wound-healing process.¹⁵ These MSCs can release pro-regenerative cytokines and growth factors such as TGF- β , VEGF and PDGF, which function to activate cells that play a role in forming new skin tissue.¹⁶ Based on this background, a study was conducted on the effect of human Bone Marrow Stem Cells on healing burns in the formation of granulation tissue in DM rats.

METHODS

This was an experimental study with a post-test-only control group design. The research was conducted at the animal house of the faculty of pharmacy and the laboratory of anatomical pathology in the faculty of medicine, Universitas Andalas. The population used in this study were white rats (*Rattus norvegicus*) which were injected with alloxan to increase their blood sugar which met the inclusion and exclusion criteria. Inclusion criteria: (1) Wistar strain male white rats are healthy and active and have never been used for research, (2) Rats are two months old, (3) Mice have a body weight ranging from 200-300 g, (4) Rats induced by alloxan, his blood sugar increased > 1 ½ from the beginning. Exclusion criteria: Mice died during the study.

Determination of sample size is based on criteria set by World Health Organization (WHO); in experimental animal studies, the minimum number of samples required for each group is five rats, and the total object of research is 30 rats. Mice were divided into control and treatment groups, the control group was injected with PBS and the treatment group was injected with hBM-MSCs. Stem cells were given subcutaneously at a dose of 2 x 10⁶ cells/ml. Before being treated, the rats were anesthetized using xylazine and ketamine; then the rats were given full-

thickness burns on the dorsal (back) side. Tissue collection was carried out after the termination of the experimental animals on the 3rd, 7th and 14th days, and then histological preparations were made to assess the formation of granulation tissue. Histopathological preparations were made by staining with hematoxylin-eosin (HE).

The results of observations in the form of differences in histopathological features in the wound tissue of experimental animals were recorded, tabulated and statistically analyzed using a computerized system with 95% confidence intervals and a significance level of 0.05 ($p = 0.05$). First, the data normality and variance homogeneity tests were

carried out on all variables, then analyzed using two-way ANOVA and post-hoc Bonferoni tests. If the data is not normally distributed, Friedmann's alternative test is performed.

This research has received approval from the ethical committee of the Faculty of Medicine, Andalas University, with the ethical number 597/UN.1.6.2/KEP-FK/2022.

RESULTS

After researching the influence of human Bone Marrow Mesenchymal Stem Cells on the formation of granulation tissue, the following results were obtained.

Table 1. Results of observation and analysis after being given human bone marrow mesenchymal stem cells on inflammatory cells (neutrophils, lymphocytes, macrophages), fibroblasts and new blood vessels

Variable	Day	Control	Treatment	
Neutrophils	Day 3	13.44 ± 5.74	16.48 ± 4.52	0.586
	Day 7	11.72 ± 2.16	12.04 ± 4.58	
	Day 14	4.48 ± 2.35	3.04 ± 0.74	
Lymphocytes	Day 3	2.02 ± 0.97	1.52 ± 0.27	0.002
	Day 7	6.72 ± 2.65	11.04 ± 6.05	
	Day 14	1.84 ± 2.78	4.32 ± 0.54	
Macrophages	Day 3	1.24 ± 0.98	1.52 ± 1.25	0.033
	Day 7	7.64 ± 2.17	20.12 ± 6.31	
	Day 14	18.44 ± 9.07	19.02 ± 7.02	
Fibroblasts	Day 3	6.04 ± 1.27	8.88 ± 2.28	0.001
	Day 7	10.96 ± 3.98	13.00 ± 4.21	
	Day 14	19.28 ± 1.17	33.84 ± 4.33	
New Blood vessel	Day 3	3.48 ± 1.93	7.08 ± 1.33	0.000
	Day 7	10.24 ± 3.51	15.56 ± 0.93	
	Day 14	10.68 ± 0.78	11.77 ± 3.43	

In table 1, it can be seen that in the treatment with human bone marrow mesenchymal stem cells, there was a significant difference ($p < 0.05$) in the number of lymphocytes, macrophages, fibroblasts and new blood vessels, respectively, namely 0.002, 0.033, 0.001 and 0.001, but there was no significant

difference in the number of neutrophils, namely 0.586. This difference can also be seen in Figures 1 and 2 which show an increase in the number of lymphocytes, macrophages, fibroblasts, and new blood vessels in each group.

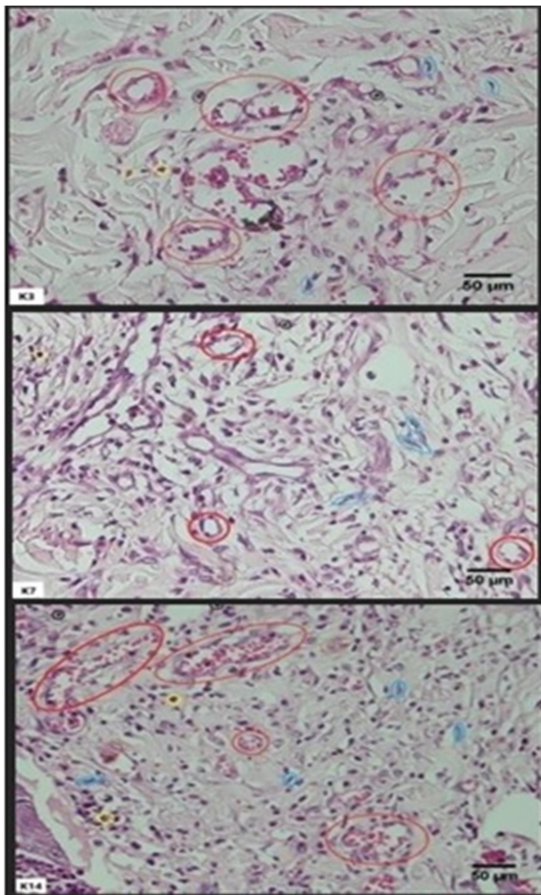


Figure 1. Granulation tissue in the control group on days 3, 7 and 14. Number of blood vessels (red), fibroblasts (blue), lymphocytes (black), macrophages (brown), neutrophils (yellow). [400x]

DISCUSSION

The results of observations on histopathological preparations on the formation of granulation tissue in full-depth burn rats by counting the number of inflammatory cells (neutrophils, lymphocytes and macrophages), fibroblasts and new blood vessels found that human Bone Marrow Mesenchymal Stem Cells influence the number of neutrophils, lymphocytes, macrophages, fibroblasts and new blood vessels. In a histopathological observation on the third day after the wound, it was found that the number of neutrophils increased. This condition showed that there was still inflammation. On day 14, the number of neutrophils decreased. It can be said that hBM-MSC plays a role in suppressing inflammation. On the seventh day, other inflammatory cells such as lymphocytes, macrophages, fibroblasts and new blood vessels, saw a significant increase. It is known that the number of inflammatory cells increases at the start of an injury as neutrophils are most commonly found

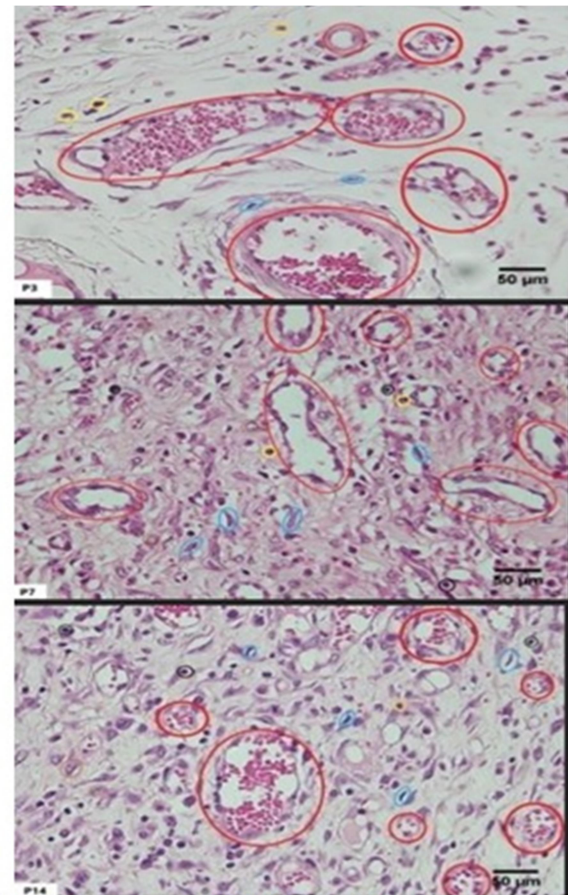


Figure 2. Granulation tissue in the treatment group shows an increase in the number of blood vessels (red), fibroblasts (blue), lymphocytes (black), macrophages (brown) and neutrophils (yellow). [400x]

on the first and second day of the wound, macrophages on the first day to the fifth day and lymphocytes are mostly found from the fourth to the seventh day.^{11,17}

Research on BM-MSC in wounds with DM that has been carried out is known to reduce the inflammatory response in rats with diabetes and also, therapy with BM-MSC may be given to chronic wounds.¹⁸ In other studies, it is known that BM-MSC will reduce the progression of burns through immunomodulatory effects by reducing neutrophil infiltration and reducing the expression of pro-inflammatory cytokines in local tissues¹⁹, and increasing the anti-inflammatory cytokine IL-10.²⁰

Granulation tissue formation is the most important wound healing in the proliferative phase. The granulation tissue consists of inflammatory cells, fibroblasts, new blood vessels, and collagen.¹⁷ Macrophages present in the wound will produce growth factors needed for fibroplasia and also

angiogenesis, such as Transforming growth factor- β (TGF- β), Platelet-derived growth factor (PDGF) and Vascular endothelial growth factor r (VEGF). PDGF will attract fibroblasts to the wound site and then, together with TGF- β , stimulates fibroblast proliferation in the wound.²¹

In this study, there was a significant difference in the number of fibroblasts between the control group and the treatment group given hBM-MSCs. This is because hBM-MSCs have the ability to differentiate into various types of cells by releasing various factors to accelerate the wound-healing process. These factors are in the form of pro-regenerative cytokines as well as growth factors such as PDGF, TGF- β and VEGF, which aim to stimulate the formation of collagen released by paracrine signaling effects.³ Paracrine signaling of hBM-MSCs can reduce inflammation, accelerate angiogenesis and induce migration and fibroblast proliferation.²²

The group that was given injections of Mesenchymal Stem Cells experienced an increase in epidermal regeneration and an increase in reepithelialization and an increase in the thickness of collagen fibers on day 14 compared to the control group because the wound healing mechanism is influenced by paracrine signaling so that it will trigger the production of EGF, VEGF and KGF as well as FGF.²³ Research by Xu *et al.* (2017) showed that in diabetic wounds, it can reduce the content of collagen I and III, given MSCs therapy can significantly increase the content of collagen I in diabetic and non-diabetic wounds.²⁴

In this study, the number of fibroblasts between groups was more in the treatment group than the control group and showed an increase from the 3rd, 7th to 14th day. Similar to the study conducted by Fridoni *et al.* (2019) using hBM-MSC on diabetic wounds, it was found that fibroblasts experienced a significant increase from day 4, day 7 to day 15.¹⁸ This could also be due to the number increased leukocytes, then there is an increase in the production of cytokines that play a role in the proliferative process, fibroblasts. During the inflammatory phase of wound healing, IL-1 and TNF- α will increase and are known to activate fibroblasts by increasing Fibroblasts Growth Factor (FGF) in wounds.²² In addition to producing growth

factors for the formation of fibroblasts, Macrophages also produce a growth factor, namely VEGF, which plays an important role in forming blood vessels or angiogenesis. The movement of endothelial cells marks angiogenesis and the formation of new capillaries as a natural response to growth factors.²⁵

In a study by Kong *et al.* (2013) also said that the administration of Mesenchymal Stem Cells to diabetic Goto-Kakizaki rats plays a very important role in the process of angiogenesis through the secretion of proangiogenic molecules such as bFGF, VEGF, TGF- β , IGF-1 and HGF.²⁶ Goto-Kakizaki rats are animals for type 2 DM because it provides a clinical picture in DM patients. Spontaneously becomes DM through various mechanisms of modifying genes, damaging gestational metabolism resulting in disturbances in organs such as the pancreas, which are the main target of insulin.²⁷

Research conducted by Kuo *et al.* (2016) using diabetic rats found that Mesenchymal Stem Cells can stimulate neoangiogenesis and increase tissue regeneration. These MSCs carry out the migration to the wound margins and increase angiogenesis through the activation of endothelial activity by increasing VEGF levels in wound healing. New blood vessels are very important in the wound healing process because the formation of granulation tissue requires oxygen and nutrients supplied from blood vessels. If this process does not occur then the wound-healing process will be hampered so that the wound becomes chronic.²⁸

This research has been carried out in accordance with existing procedures, but of course, there are still research limitations, namely the lack of observation time because the formation of granulation tissue lasts until the 21st day, so an overall comparison cannot be seen.

CONCLUSION

There is an effect of Human Bone Marrow Mesenchymal Stem Cells on the formation of lymphocytes, macrophages, fibroblasts and new blood vessels while neutrophils are not affected by the administration human Bone Marrow Mesenchymal Stem Cell in diabetes mellitus rats.

BIBLIOGRAPHY

1. Keputusan Menteri Kesehatan nomor HK.01.07/MENKES/555/2019 tahun 2019 pedoman nasional pelayanan kedokteran tata laksana luka bakar
2. Roshangar L, Rad JS, Kheirjou R, Ranjkesh MR, Khosroshasi AF. Skin burns: Review of molecular mechanisms and therapeutic approaches. *Wounds*. 2019;31(12):308-15.
3. Stone R, Natesan S, Kowalczewski CJ, Mangum LH, Clay NE, Clohelssy RM, *et al*. Advancements in regenerative strategies through the continuum of burn care. *Front Pharmacol*. 2018;9:672.
4. Primadina N, Basori A, Perdanakusuma DS. Proses penyembuhan luka ditinjau dari aspek mekanisme seluler dan molekuler. *Qanun Med*. 2019;3(1):31-43.
5. Krafts KP. Tissue repair: The hidden drama. *Organogenesis*. 2010;6(4):225-33.
6. Martins-Green M, Petreaca M, Wang L. Chemokines and their receptors are key players in the orchestra that regulates wound healing. *Adv Wound Care (New Rochelle)*. 2013;2(7):327-47.
7. Baltzis D, Eleftheriadou I, Veves A. Pathogenesis and treatment of impaired wound healing in diabetes mellitus: New insights. *Adv Ther*. 2014; 31 (8):817-36.
8. Tanuwijaya PA, Berata IK, Jayawardhita AAG. Pemberian gel ekstrak daun binahong dalam proses angiogenesis penyembuhan luka insisi pada mencit hiperglikemia. *Indones Med Veterinus Juli*. 2019; 8 (4):523-31.
9. Anggraeni D, Airin CM, Raharjo S. The effectiveness of ethanol extract of binahong leaves on diabetic wound healing. *J Kedokt Hewan - Indones J Vet Sci*. 2018;11(4):146-52.
10. Hu MS, Leavitt T, Malhotra S, Duscher D, Pollhammer MS, Walmsley GG, *et al*. Stem cell-based therapeutics to improve wound healing. *Plast Surg Int*. 2015:383581.
11. Hartono B. Sel Punca: Karakteristik, potensi dan aplikasinya. *J Kedokt Meditek*. 2016;22(60):72-5.
12. Sierra-Sánchez Á, Montero-Vilchez T, Quiñones-Vico MI, Sanchez-Diaz M, Arias-Santiago S. Current advanced therapies based on human mesenchymal stem cells for skin diseases. *Front Cell Dev Biol*. 2021;9:643125.
13. Revilla G. Pengaruh bone marrow mesenchymal stem cells terhadap sekresi VEGF pada penyembuhan luka bakar tikus. *J Kesehat Andalas*. 2017;6(3):702-6.
14. Chen JS, Wong VW, Gurtner GC. Therapeutic potential of bone marrow-derived mesenchymal stem cells for cutaneous wound healing. *Front Immunol*. 2012;3:192.
15. Kareem NA, Aijaz A, Jeschke MG. Stem cell therapy for burns: story so far. *Biologics*. 2021;15:379-97.
16. Lee DE, Ayoub N, Agrawal DK. Mesenchymal stem cells and cutaneous wound healing: Novel methods to increase cell delivery and therapeutic efficacy. *Stem Cell Res Ther*. 2016;7:37.
17. Broughton G, Janis JE, Attinger CE. The basic science of wound healing. *Plast Reconstr Surg*. 2006;117(7 Suppl):12S-34S.
18. Fridoni M, Kouhkeheil R, Abdollahifar MA, Amini A, Ghatrehsamani M, Goreishi SK, *et al*. Improvement in infected wound healing in type 1 diabetic rat by the synergistic effect of photobiomodulation therapy and conditioned medium. *J Cell Biochem*. 2019;120(6):9906-16.
19. Abbas OL, Özatik O, Gönen ZB, Ogut S, Entok E, Ozatik FY, *et al*. Prevention of burn wound progression by mesenchymal stem cell transplantation: deeper insights into underlying mechanisms. *Ann Plast Surg*. 2018;81(6):715-24.
20. Hosni Ahmed H, Rashed LA, Mahfouz S, Hussein RE, Alkaffas M, Mostafa S, *et al*. Can mesenchymal stem cells pretreated with platelet-rich plasma modulate tissue remodeling in a rat with burned skin? *Biochem Cell Biol*. 2017;95(5):537-48.
21. Gonzalez ACDO, Andrade ZDA, Costa TF, Medrado ARAP. Wound healing - A literature review. *An Bras Dermatol*. 2016;91(5):614-620.
22. Barrientos S, Stojadinovic O, Golinko MS, Brem H, Tomic-Canic M. Growth factors and cytokines in wound healing. *Wound Repair Regen*. 2008;16(5):585-601.
23. Revilla G. Pengaruh bone marrow mesenchymal stem cells terhadap sekresi VEGF pada penyembuhan luka bakar tikus. *J Kesehat Andalas*. 2017;6(3):702-6.

24. Xu J, Zgheib C, Hodges MM, Caskey RC, Hu J, Liechty KW. Mesenchymal stem cells correct impaired diabetic wound healing by decreasing ECM proteolysis. *Physiol Genomics*. 2017;49(10):541-8.
25. Prasetyono TOH. General concept of wound healing. *Med J Indones*. 2009;18(3):208-16.
26. Kong P, Xie X, Li F, Liu Y, Lu Y. Placenta mesenchymal stem cell accelerates wound healing by enhancing angiogenesis in diabetic Goto-Kakizaki (GK) rats. *Biochem Biophys Res Commun*. 2013;438(2):410-9.
27. Husna F, Suyatna FD, Arozal W, Purwaningsih EH. Model Hewan Coba pada Penelitian Diabetes. *Pharm Sci Res*. 2019;6(3):131-41.
28. Kuo YR, Wang CT, Cheng JT, Kao GS, Chiang YC, Wang CJ. Adipose-derived stem cells accelerate diabetic wound healing through the induction of autocrine and paracrine effects. *Cell Transplant*. 2016;25(1):71-81.